

Lateral Robotic Unicompartmental Knee Arthroplasty

Ran Thein, MD,* Saker Khamaisy, MD,*† Hendrik A. Zuiderbaan, MD,*
Danyal H. Nawabi, MD,† and Andrew D. Pearle, MD*†

Abstract: Robotic-assisted unicompartmental knee arthroplasty (UKA) is accurate and repeatable. Lateral UKA is still considered a challenge, as the lateral side of the knee has different anatomy and kinematics compared with the medial side. The lateral compartment of the knee is less constrained than the medial compartment and is therefore less tolerant for mobile-bearing implants and ACL deficiency. However, the long-term outcomes of lateral UKA are scarce. Moreover, the impact of patellofemoral joint degeneration on the outcome of lateral UKA is unknown. We report our preliminary results with fixed bearing robotic-assisted lateral UKA, which are encouraging in the short term.

Key Words: lateral compartment, robotic unicompartmental arthroplasty, computer-assisted surgery

(*Sports Med Arthrosc Rev* 2014;22:223–228)

Unicompartmental knee arthroplasty (UKA) is gaining popularity in the treatment of patients with isolated knee compartment osteoarthritis (OA).¹ Compared with total knee arthroplasty (TKA), the results of UKA are superior with regard to restoration of normal knee kinematics,² perioperative morbidity, blood loss, infection rates, knee range of motion (ROM), and recovery time.^{3–10}

Isolated lateral compartment OA accounts for only 5% to 10% of knee OA cases^{11–14} and not surprisingly, lateral UKA comprises only 1% of all knee arthroplasties performed.¹² Lateral UKA is considered a more demanding procedure compared with medial UKA. Although early studies reported superior results of lateral UKA comparing to medial UKA,^{15,16} improvements in surgical technique and implant design has led to better survivorship of medial UKA.^{17,18} The improved survivorship has been attributed to the differences in anatomy and kinematics between the lateral and the medial compartments of the knee. For example, the hypermobility of the lateral compartment has been proposed as one of the explanations for the higher incidence of polyethylene dislocation in mobile-bearing lateral UKA implants.¹⁷ Computer-assisted orthopedic surgeries have been shown to improve postoperative leg alignment when compared with conventional UKA.^{19,20} Recently, a robotic-assisted surgery for UKA (MAKO Surgical Corp., Fort Lauderdale, FL) was introduced and became the first robotic arm-assisted technique for minimal invasive UKA.²¹ This new robot is “semiactive,”²² where by the surgeon is guided to work under haptic boundaries around specific surgical

targets. These boundaries and targets are determined by preoperative computed tomography (CT)-based planning with continuous intraoperative visual feedback.²²

This new robotic technique has been shown to improve postoperative implant positioning, lower extremity alignment, and to be more accurate and less variable than manual techniques in UKA.^{23–25} However, the clinical effect of it has not been shown yet as long-term clinical trials are still missing.

The purposes of this review are to discuss the differences in anatomy and kinematics between the medial and the lateral compartment of the knee, to describe the operative management of patients who undergo robotic-arm lateral UKA, and to review the outcomes of lateral UKA.

LATERAL COMPARTMENT ANATOMY AND KINEMATICS

Anatomy and kinematics of the lateral compartment of the knee are different from the medial side.^{11,26} The lateral compartment is more mobile than the medial compartment. During flexion, the tibia rotates internally with the center of rotation located on the medial side of the knee.^{27,28} These findings have been confirmed by in vivo 3-dimensional (3D) weight-bearing kinematics using fluoroscopy and CT.²⁹ These kinematics lead to excessive internal rotation of the lateral tibial compartment, which results in lateral femoral condyle posterior translation as compared with the medial femoral condyle.^{27,30,31} Furthermore, the bony anatomy differs between the 2 compartments. The sagittal tibial slope is greater on the lateral side and the lateral tibial condyle is convex in the sagittal plane, whereas the medial condyle is concave. These differences in biomechanics explain the differences in wear patterns after TKA and the occurrence of cartilage wear in the native knee.^{11,32,33} Medial compartment disease usually involves the anteromedial aspect of the tibia and symptoms are more prevalent in extension (while walking or getting up from a seated position with the knee in moderate flexion). In lateral compartment disease the symptoms are more pronounced when rising from a deep seated position or during stair climbing (flexion disease). Lateral compartment disease usually causes posterolateral wear on the tibia and on the femur.

Burton et al³⁴ reported the wear patterns following medial and lateral UKA using fixed or mobile-bearing implants in a knee simulator designed for wear analysis. Fixed-bearing implants had less wear compared with the mobile-bearing UKA. Nevertheless, in both types of implants, the lateral compartment had higher wear volume.

The passive and dynamic stabilizers of the compartments are also different. On the medial side knee stability is supported by the medial collateral ligament, a strong and isometric ligament. However, the lateral side is supported mainly by dynamic stabilizers such as the popliteal muscle and iliotibial tract.³⁵ Moreover, the lateral compartment can be distracted on average up to 7 mm compared with the medial side which is limited to 2 mm distraction.³⁶

From the *Department of Orthopedic Surgery, Computer Assisted Surgery Center; and †Sports Medicine and Shoulder Service, Department of Orthopedic Surgery, Hospital for Special Surgery, Weill Medical College of Cornell University, New York, NY.

Disclosure: Andrew D. Pearle: Consultant for Stryker Mako and Biomet. The remaining authors declare no conflict of interest.

Reprints: A. D. P., MD, Hospital for Special Surgery, 535 East 70th street, New York, NY 10021

Copyright © 2014 by Lippincott Williams & Wilkins

Therefore, inferior outcomes were reported with the use of mobile-bearing implants in the lateral compartment compared with the medial compartment, mainly due to the polyethylene insert dislocation rate.^{17,37} Robotic UKA utilizes a fixed-bearing implant (MCK Medial Onlay Unicompartmental; MAKO Surgical Corp.), which may result in a lower failure rate in the lateral compartment.

PATIENT SELECTION AND PREOPERATIVE EVALUATION

The indication for lateral robotic UKA should be based on the clinical history and examination followed by a radiographic evaluation. The indications for lateral UKA are more restricted compared with medial UKA.¹² The primary symptom is knee pain, located to the lateral compartment with no medial compartment-related pain. Patellofemoral joint (PFJ) degenerative changes are not considered a contraindication, but patients should be excluded if they experience anterior knee pain related to the PFJ degeneration. Some authors consider type-4 PFJ degenerative changes (Outerbridge classification) or PFJ-related pain as contraindications to lateral UKA.^{11,26,38,39} We retrospectively looked at 19 patients with no preoperative PFJ-related pain after lateral robotic UKA. No correlation was found between PFJ congruence and PFJ degenerative changes before the surgery and clinical outcomes (WOMAC) on an average of 2 years of follow-up (Ran Thein, MD and Andrew D. Pearle, MD; 2013, unpublished data). To the best of our knowledge, there is no published study about the influence of the PFJ on lateral UKA. Although UKA may be indicated and reported with rheumatoid arthritis,²⁶ inflammatory arthritis remains a subject of debate, and most authors consider it as a contraindication.^{14,40} Moreover, patients should also be assessed based on their general medical condition as UKA have been reported to have less perioperative complications than TKA.⁷

On examination, coronal and sagittal alignment as well as ROM should be recorded. Our indications for lateral robotic UKA are a fixed-flexion deformity of <10 degrees and knee flexion of ≥ 100 degrees, correctable valgus deformity which is assessed clinically compared with the contralateral leg. If the clinical examination is not conclusive, additional stress radiographs have to be performed. Anteroposterior (AP) laxity should be evaluated as well. ACL deficiency (ACLD) as a contraindication to medial UKA remains a matter of debate.⁴¹ However, the lateral compartment's inherent hypermobility significantly increases in ACLD knees.^{42,43} Therefore, patients with ACLD have been excluded from lateral robotic UKA.^{44,45}

Obesity is considered by some as an exclusion criterion in lateral UKA. The authors do not exclude performing TKA in those patients.⁴⁰ However, overweight is not considered as contraindication by others.^{14,26,46} We consider body mass index >35 as contraindication for lateral UKA.

Radiographic evaluation includes lateral and standing AP x-rays,^{14,47} skyline or Merchant views, and hip to ankle standing film for determination of alignment.^{11,40} In addition, posteroanterior (PA) radiographs such as the Rosenberg view⁴⁸ might be added as an additional tool to the regular AP radiographs for assessing the typical posterior tibia cartilage wear on the lateral side. On AP and PA radiographs, arthritis should be limited to the lateral compartment of the knee with significant loss of joint space.^{46,49–52} However, we do not consider osteophytes or chondrocalcinosis as contraindication if the medial

compartment joint space is preserved.¹⁴ Few authors have recommended varus and valgus stress radiographs for evaluating joint space and the ability to correct valgus deformity.^{40,46,53} We consider insufficiency of the medial stabilizers and a fixed valgus deformity to be contraindications for lateral UKA.^{26,46,53}

OPERATION TECHNIQUE

Detailed description of the operation room setting before the surgery and technical issues related to the robotic UKA surgical procedure in general have been reported in the past.²²

Briefly, on preoperative assessment, CT scans are obtained for all patients. Using the software of the Tactile Guidance System (TGS; MAKO Surgical Corp.), all CTs are segmented, defined, and recombined to produce 3D models of the femur and tibia. Implant models are then positioned, with corresponding cement mantles on the reconstructed bone models, resulting in patient-specific CT-based planning²² (Fig. 1).

In the OR, the TGS is placed before the patient arrives. After sterile draping of the patient and the robotic arm, a 3D calibration is applied. Few authors have reported the medial parapatellar approach for lateral UKA with surgeons more familiar with conversion to TKA, if needed.^{11,26} We usually performed lateral robotic UKA through lateral parapatellar incision. Our incision is about 2.5 to 3 inches long which is about 0.5 inch more than for medial UKA to allow patellar subluxation without causing damage to the extension mechanism. For the same reason, patellar subluxation is performed in 45 degrees of flexion. Compared with the manual UKA which is based on cutting jigs with a saw, the robotic UKA is performed with a 6 mm burr which is safer for working adjacent to the extension mechanism especially in more demanding lateral UKA surgery.

After knee registration based on the preoperative CT is completed and osteophytes are removed followed by release of soft-tissue adhesions, a dynamic soft-tissue gap balancing algorithm is initiated. Full ROM of the knee joint is evaluated. A knee pose (assessment of coronal alignment) is taken in full extension to define the initial limb alignment. The knee is then taken to 10 degrees of flexion to release the tension in the posterior capsule, and a varus stress is added to the knee, while dynamically evaluating the mechanical axis. Once the desired correction is achieved, it is defined and registered in the system and the knee is now taken through a full ROM. A visual representation of the tibial and femoral components relationship is displayed, using bar graph, for each captured pose angle. Each bar represents knee tightness or looseness at different angles. A major advantage of CAS is this virtual modeling of the knee and intraoperative tracking. This allows real-time adjustment to achieve correct knee kinematics and soft-tissue balancing before performing any bony cuts. On the basis of gait analysis, we aim to undercorrect the mechanical axis after lateral UKA (valgus of 1 to 3 degrees) (Fig. 2). During weight bearing, in intact knees, load is shifting to the medial side of the knee. Locomotion studies have shown that during the stance phase, the knee experiences a valgus moment at the very beginning (heel-strike) followed by a varus moment with 2 distinct peaks.⁵⁴ This gait pattern is our major reason for the mechanical alignment undercorrection. If overcorrection is applied, the medial compartment will experience overload which might lead to early failure. It has been shown that overcorrection on the medial side is correlated with higher incidence of failure.⁵⁵

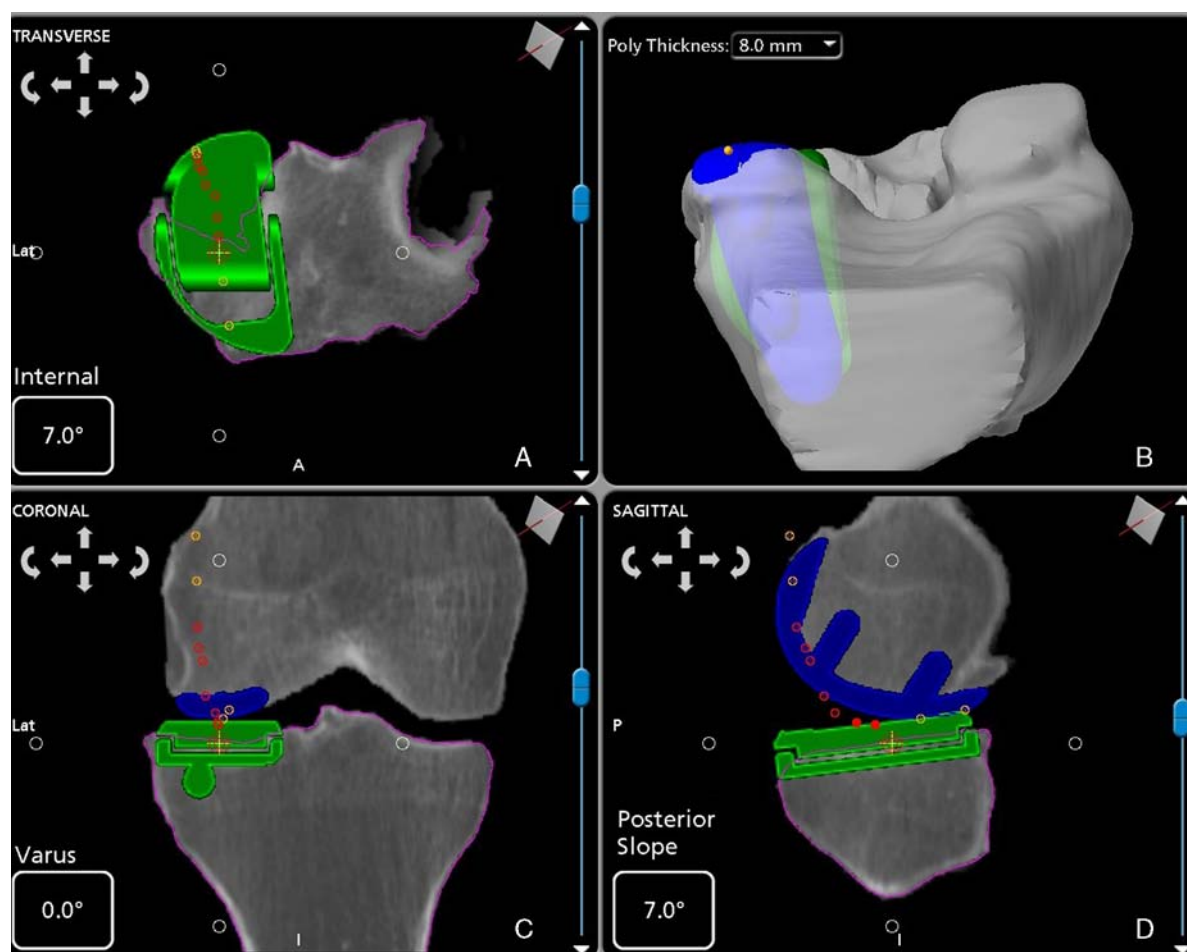


FIGURE 1. Preoperative templating. All patients undergo CT scanning before surgery. Computer-assisted design models of the implanted components are templated onto the 3D reconstructed images using computer software. A, Axial view of the virtual tibial component on the tibia. The implant is 3 degrees internally rotated relative to the tibia. B, Axial view of the tibial and the femoral virtual components. C, Coronal view of the knee with the virtual implants. The tibial component is in 0.1 degrees of varus related to the tibial axis. D, Sagittal view of the knee with the virtual implants. The tibial component has 5 degrees of posterior slope related to the axis of the tibia.

In a preliminary study, we compared the mechanical axis correction between medial and lateral robotic UKA (229 knees and 37 knees, respectively). Overcorrection was noticed in 4% of the medial UKA, and 11% of the lateral UKA (Andrew D. Pearle, MD; 2013, unpublished data). The difference between the preoperative “virtual” planning and the postoperative weight-bearing radiographic alignment was greater in lateral UKA when compared with medial UKA, 1.86 ± 1.33 and 1.33 ± 1.2 degrees, respectively ($P = 0.019$). These data suggest that lateral compartment replacement is more prone to overcorrection, even when using CAS and the robotic-arm technique [These data were presented at International Society for Technology in Arthroplasty (ISTA), 2013, Palm Beach, FL]. We recommend strict attention to intraoperative evaluation of alignment correction in lateral UKA.

After all adjustments are implemented in the software, the plan can be executed by the surgeon using the robotic arm. A high-speed burr is attached to the distal end of the robotic arm. The surgeon moves the arm by guiding its force-controlled tip within the predefined boundaries. The robot gives the surgeon active tactile, visual, and auditory feedback during burring. If there is an attempt to use the robotic arm

outside of the boundaries, the robot causes auditory feedback and motion resistance to keep the burr within the accepted volume. In addition, the cutting instrument will immediately stop if there is excessive force at the limits of the 3D cutting volume or rapid movement of patient anatomy. The femoral side is prepared first, starting at the most anterior and proximal part of the lateral femoral condyle and proceeding with caution as to not injure the patella. When burring the posterior condyle, the knee needs to be in 110 degrees of flexion. Once the femoral side is ready, the tibial side is then addressed. The knee is flexed to 100 degrees for preparation of the lateral tibial plateau.

The average surgical time is about 60 minutes, including 15 minutes of exposure and registration. Usually the patients are discharged from hospital on the day following the surgery and are allowed to weight bear as tolerated.

LATERAL UKA OUTCOMES

Traditionally, lateral UKA is considered more technically demanding than medial UKA. The introduction of CAS with a robotic-arm technique may facilitate the

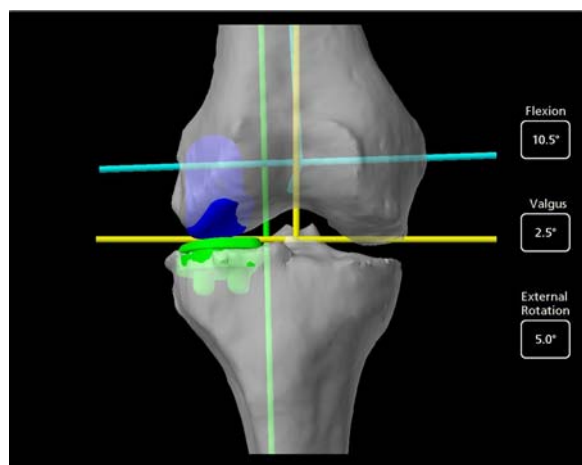


FIGURE 2. “Virtual” mechanical axis. The “virtual” intraoperative coronal mechanical axis as perceived by the robotic device during the procedure, in this case 2.5 degrees of valgus (182.5 degrees).

procedure and lead to better repeatability. Lonner et al²⁴ have shown that by using CAS with robotic-arm technique implant alignment errors were decreased. The authors reported that in the conventional manual technique, mean tibial slope error was 3.1 degrees compared with 1.9 degrees

using the robotic technique. Moreover, the variance of the implant alignment was 2.6 times less in the robotic method. In the coronal plane, the average error of tibial alignment was only 0.2 degrees of varus compared with 2.7 degrees with the manual technique.²⁴ Cobb and colleagues have reported significant improvements in root mean square (RMS) implant placement Errors between the manual technique and the robotic technique. Compared with a manual technique, the robotic surgery reduced the medio-lateral error from 2.6 to 1 mm, the AP error from 2.4 to 1.8 mm, and the proximal-distal error from 1.6 to 0.6 mm. We performed a cadaveric study implanting UKA using robotic technique on the right side and manual technique on the left side. RMS implant placement errors for femoral component were within 1.9 mm and 3.7 degrees in all directions of the planned implant position for the robotic group, whereas RMS errors for the manual group were within 5.4 mm and 10.2 degrees. Average RMS implant placement errors for tibial component were within 1.4 mm and 5.0 degrees in all directions for the robotic group, whereas for the manual group, RMS errors were within 5.7 mm and 19.2 degrees.⁵⁶ Moreover, flexion-extension, varus-valgus, and rotations errors were significantly reduced as well.²³ These results have been supported by Dunbar et al.²⁵ However, there are no published studies reporting long-term clinical outcomes of robot-assisted lateral UKA. In our preliminary study, we evaluated 25 patients (26 knees) for clinical and radiographic outcomes

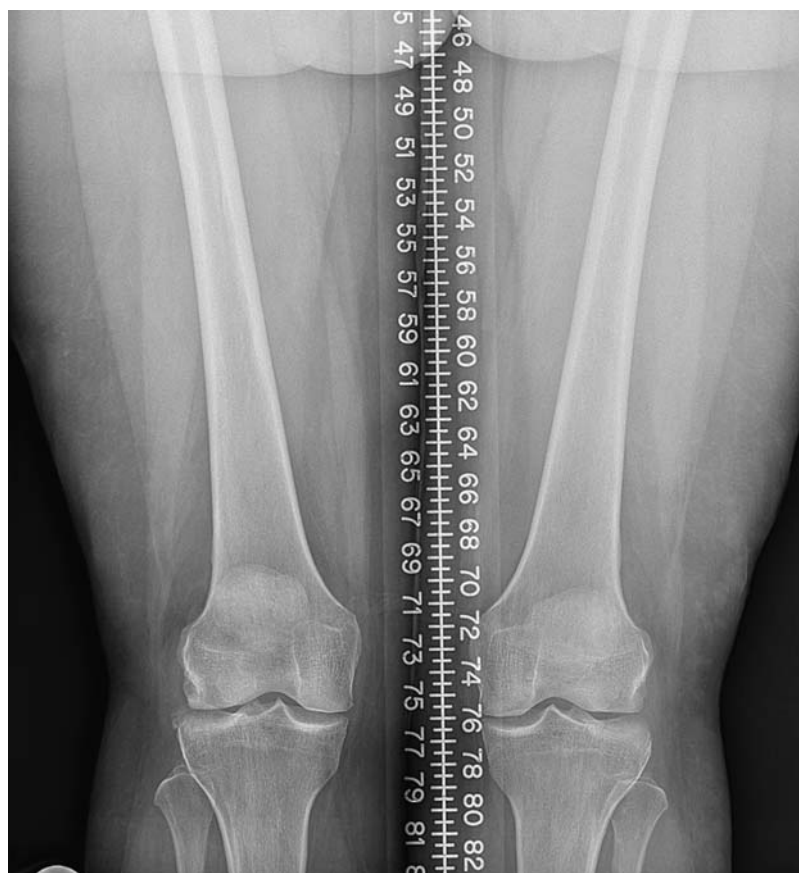

FIGURE 3. A right knee preoperative anteroposterior full weight-bearing radiograph of a 56-year-old female with lateral compartment degenerative changes.

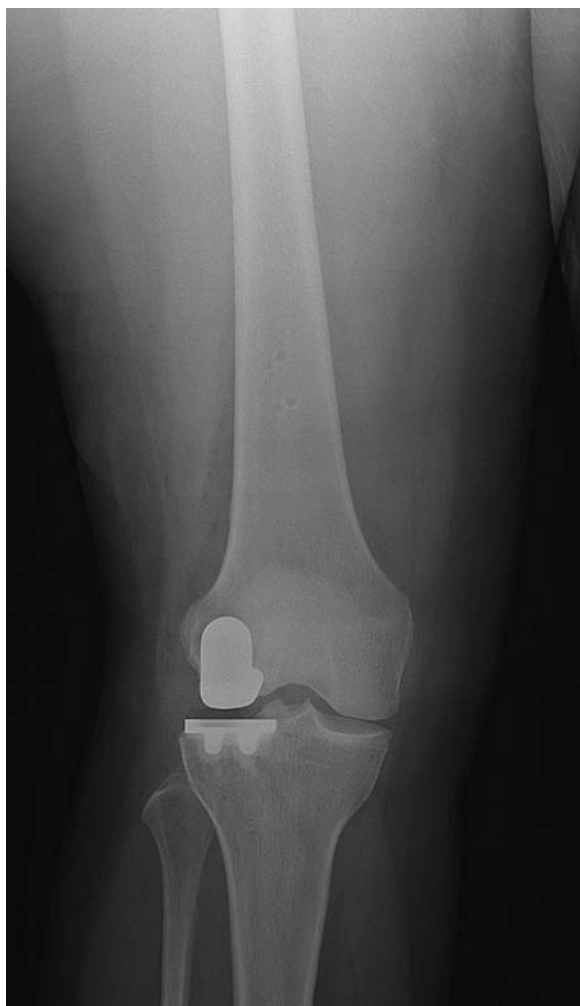

FIGURE 4. A right knee postoperative anteroposterior radiograph of a 56-year-old female following lateral robotic unicompartmental arthroplasty.

at an average of 2 years after robotic lateral UKA (Figs. 3, 4). The average age of patients was 63 ± 13 years, body mass index was 26.35 ± 4.7 , and Kellgren-Lawrence (K-L) grade was 2.5 ± 1 . Preoperatively, the mechanical axis of the operating leg was on average 4.1 degrees of valgus, which improved to 1.64 degrees postoperatively.

WOMAC scores improved significantly ($P < 0.001$) at 2-year follow-up. In our series, there were no complications, revisions, or conversions to TKR (Andrew D. Pearle, MD; 2013, unpublished data). Additional investigation, with long-term clinical outcomes, comparing conventional and robotic UKA is needed to determine whether this difference will stay significant. Moreover, the cost-effectiveness of robotic UKA when compared with conventional UKA is still unknown.

Historical studies published in the 70s showed that the outcomes of lateral UKA were superior to medial UKA.^{15,16} However, improvements in design and surgical technique have led to improved medial UKA outcomes over the lateral UKA particularly with mobile-bearing implants.^{17,18} Recently, few studies have shown encouraging lateral UKA outcomes.^{46,51,57} At long-term follow-up

series reported by Argenson et al⁴⁶ has shown that Knee Society pain and function scores were improved significantly and prostheses survivorship was 92% at 10 years and 84% at 16 years.

CONCLUSIONS

Lateral UKA is still considered a challenging procedure. Compared with the medial compartment, the lateral compartment is less constrained and has a different anatomic structure which leads to hypermobility. Furthermore, lateral UKA is 10 times less commonly performed than medial UKA. The CAS with robotic arm is a new surgical-assisted technology. It enables meticulous preplanning and has the ability to reevaluate intraoperative knee kinematics, alignment, and the knee path of movement. Moreover, it has been shown to produce more accurate and repeatable UKA implant alignment compared with the conventional UKA technique. However, patient selection, preoperative clinical and radiographic evaluation, and surgical technique are still the critical requirements for lateral UKA success.

REFERENCES

1. Borus T, Thornhill T. Unicompartmental knee arthroplasty. *J Am Acad Orthop Surg.* 2008;16-1:9–18.
2. Hanson GR, Moynihan AL, Suggs JF, et al. Kinematics of medial unicompartmental knee arthroplasty: an in vivo investigation. *J Knee Surg.* 2009;22-3:237–242.
3. Newman J, Pydisetty RV, Ackroyd C. Unicompartmental or total knee replacement: the 15-year results of a prospective randomised controlled trial. *J Bone Joint Surg Br.* 2009;91-1:52–57.
4. Mullaji AB, Shetty GM, Kanna R. Postoperative limb alignment and its determinants after minimally invasive Oxford medial unicompartmental knee arthroplasty. *J Arthroplasty.* 2011;26-6:919–925.
5. McAllister CM. The role of unicompartmental knee arthroplasty versus total knee arthroplasty in providing maximal performance and satisfaction. *J Knee Surg.* 2008;21-4:286–292.
6. Mullaji AB, Sharma A, Marawar S. Unicompartmental knee arthroplasty: functional recovery and radiographic results with a minimally invasive technique. *J Arthroplasty.* 2007;22-4(suppl 1):7–11.
7. Newman JH, Ackroyd CE, Shah NA. Unicompartmental or total knee replacement? Five-year results of a prospective, randomised trial of 102 osteoarthritic knees with unicompartmental arthritis. *J Bone Joint Surg Br.* 1998;80-5:862–865.
8. Berend KR, Lombardi AV Jr. Liberal indications for minimally invasive oxford unicompartmental arthroplasty provide rapid functional recovery and pain relief. *Surg Technol Int.* 2007;16:193–197.
9. Willis-Owen CA, Brust K, Alsop H, et al. Unicompartmental knee arthroplasty in the UK National Health Service: an analysis of candidacy, outcome and cost efficacy. *Knee.* 2009;16-6:473–478.
10. Larsen K, Sorensen OG, Hansen TB, et al. Accelerated perioperative care and rehabilitation intervention for hip and knee replacement is effective: a randomized clinical trial involving 87 patients with 3 months of follow-up. *Acta Orthop.* 2008;79-2:149–159.
11. Sah AP, Scott RD. Lateral unicompartmental knee arthroplasty through a medial approach. Study with an average five-year follow-up. *J Bone Joint Surg Am.* 2007;89-9:1948–1954.
12. Scott RD. Lateral unicompartmental replacement: a road less traveled. *Orthopedics.* 2005;28-9:983–984.
13. Laskin RS. Unicompartmental knee replacement: some unanswered questions. *Clin Orthop Relat Res.* 2001;392:267–271.
14. Pennington DW, Swienckowski JJ, Lutes WB, et al. Lateral unicompartmental knee arthroplasty: survivorship and technical considerations at an average follow-up of 12.4 years. *J Arthroplasty.* 2006;21-1:13–17.

15. Insall J, Aglietti P. A five to seven-year follow-up of unicondylar arthroplasty. *J Bone Joint Surg Am.* 1980;62-8:1329-1337.
16. Laskin RS. Unicompartmental tibiofemoral resurfacing arthroplasty. *J Bone Joint Surg Am.* 1978;60-2:182-185.
17. Gunther TV, Murray DW, Miller R, et al. Lateral unicompartmental arthroplasty with the Oxford meniscal knee. *Knee.* 1996;3:33-39.
18. Marmor L. Lateral compartment arthroplasty of the knee. *Clin Orthop Relat Res.* 1984;186:115-121.
19. Jenny JY, Ciobanu E, Boeri C. The rationale for navigated minimally invasive unicompartmental knee replacement. *Clin Orthop Relat Res.* 2007;463:58-62.
20. Keene G, Simpson D, Kalairajah Y. Limb alignment in computer-assisted minimally-invasive unicompartmental knee replacement. *J Bone Joint Surg Br.* 2006;88-1:44-48.
21. Conditt MA, Roche MW. Minimally invasive robotic-arm-guided unicompartmental knee arthroplasty. *J Bone Joint Surg Am.* 2009;91(suppl 1):63-68.
22. Roche M, O'Loughlin PF, Kendoff D, et al. Robotic arm-assisted unicompartmental knee arthroplasty: preoperative planning and surgical technique. *Am J Orthop (Belle Mead, NJ).* 2009;38-2(suppl):10-15.
23. Cobb J, Henckel J, Gomes P, et al. Hands-on robotic unicompartmental knee replacement: a prospective, randomised controlled study of the acrobot system. *J Bone Joint Surg Br.* 2006;88-2:188-197.
24. Lonner JH, John TK, Conditt MA. Robotic arm-assisted UKA improves tibial component alignment: a pilot study. *Clin Orthop Relat Res.* 2010;468-1:141-146.
25. Dunbar NJ, Roche MW, Park BH, et al. Accuracy of dynamic tactile-guided unicompartmental knee arthroplasty. *J Arthroplasty.* 2012;27-5:803.e1-808.e1.
26. Ashraf T, Newman JH, Evans RL, et al. Lateral unicompartmental knee replacement survivorship and clinical experience over 21 years. *J Bone Joint Surg Br.* 2002;84-8:1126-1130.
27. Hill PF, Vedi V, Williams A, et al. Tibiofemoral movement 2: the loaded and unloaded living knee studied by MRI. *J Bone Joint Surg Br.* 2000;82-8:1196-1198.
28. Iwaki H, Pinskerova V, Freeman MA. Tibiofemoral movement 1: the shapes and relative movements of the femur and tibia in the unloaded cadaver knee. *J Bone Joint Surg Br.* 2000;82-8:1189-1195.
29. Komistek RD, Dennis DA, Mahfouz M. In vivo fluoroscopic analysis of the normal human knee. *Clin Orthop Relat Res.* 2003;410:69-81.
30. Karrholm J, Brandsson S, Freeman MA. Tibiofemoral movement 4: changes of axial tibial rotation caused by forced rotation at the weight-bearing knee studied by RSA. *J Bone Joint Surg Br.* 2000;82-8:1201-1203.
31. Jonsson H, Karrholm J. Three-dimensional knee joint movements during a step-up: evaluation after anterior cruciate ligament rupture. *J Orthop Res.* 1994;12-6:769-779.
32. Wimmer MA, Andriacchi TP, Natarajan RN, et al. A striated pattern of wear in ultrahigh-molecular-weight polyethylene components of Miller-Galante total knee arthroplasty. *J Arthroplasty.* 1998;13-1:8-16.
33. Weidow J, Pak J, Karrholm J. Different patterns of cartilage wear in medial and lateral gonarthrosis. *Acta Orthop Scand.* 2002;73-3:326-329.
34. Burton A, Williams S, Brockett CL, et al. In vitro comparison of fixed- and mobile meniscal-bearing unicondylar knee arthroplasties: effect of design, kinematics, and condylar lift-off. *J Arthroplasty.* 2012;27-8:1452-1459.
35. Victor J, Wong P, Witvrouw E, et al. How isometric are the medial patellofemoral, superficial medial collateral, and lateral collateral ligaments of the knee? *Am J Sports Med.* 2009;37-10:2028-2036.
36. Tokuhara Y, Kadoya Y, Nakagawa S, et al. The flexion gap in normal knees. An MRI study. *J Bone Joint Surg Br.* 2004;86-8:1133-1136.
37. Saxler G, Temmen D, Bontemps G. Medium-term results of the AMC-unicompartmental knee arthroplasty. *Knee.* 2004;11-5:349-355.
38. Beard DJ, Pandit H, Gill HS, et al. The influence of the presence and severity of pre-existing patellofemoral degenerative changes on the outcome of the Oxford medial unicompartmental knee replacement. *J Bone Joint Surg Br.* 2007;89-12:1597-1601.
39. Beard DJ, Pandit H, Ostlere S, et al. Pre-operative clinical and radiological assessment of the patellofemoral joint in unicompartmental knee replacement and its influence on outcome. *J Bone Joint Surg Br.* 2007;89-12:1602-1607.
40. Ohdera T, Tokunaga J, Kobayashi A. Unicompartmental knee arthroplasty for lateral gonarthrosis: midterm results. *J Arthroplasty.* 2001;16-2:196-200.
41. Boissonneault A, Pandit H, Pegg E, et al. No difference in survivorship after unicompartmental knee arthroplasty with or without an intact anterior cruciate ligament. *Knee Surg Sports Traumatol Arthrosc.* 2013;21-11:2480-2486.
42. Tanaka MJ, Jones KJ, Gargiulo AM, et al. Passive anterior tibial subluxation in anterior cruciate ligament-deficient knees. *Am J Sports Med.* 2013;41-10:2347-2352.
43. Imhauser C, Mauro C, Choi D, et al. Abnormal tibiofemoral contact stress and its association with altered kinematics after center-center anterior cruciate ligament reconstruction: an in vitro study. *Am J Sports Med.* 2013;41-4:815-825.
44. Moller JT, Weeth RE, Keller JO, et al. Unicompartmental arthroplasty of the knee. Cadaver study of the importance of the anterior cruciate ligament. *Acta Orthop Scand.* 1985;56-2:120-123.
45. Deschamps G, Lapeyre B. Rupture of the anterior cruciate ligament: a frequently unrecognized cause of failure of unicompartmental knee prostheses. Apropos of a series of 79 Lotus prostheses with a follow-up of more than 5 years. *Rev Chir Orthop Reparatrice Appar Mot.* 1987;73-7:544-551.
46. Argenson JN, Parratte S, Bertani A, et al. Long-term results with a lateral unicondylar replacement. *Clin Orthop Relat Res.* 2008;466-11:2686-2693.
47. Ahlback S, Bauer GC, Bohne WH. Spontaneous osteonecrosis of the knee. *Arthritis Rheum.* 1968;11-6:705-733.
48. Rosenberg TD, Paulos LE, Parker RD, et al. The forty-five-degree posteroanterior flexion weight-bearing radiograph of the knee. *J Bone Joint Surg Am.* 1988;70-10:1479-1483.
49. Pagnano MW, Clarke HD, Jacofsky DJ, et al. Surgical treatment of the middle-aged patient with arthritic knees. *Instr Course Lect.* 2005;54:251-259.
50. Argenson JN, Parratte S, Bertani A, et al. The new arthritic patient and arthroplasty treatment options. *J Bone Joint Surg Am.* 2009;91(suppl 5):43-48.
51. Argenson JN, Blanc G, Aubaniac JM, et al. Modern unicompartmental knee arthroplasty with cement: a concise follow-up, at a mean of twenty years, of a previous report. *J Bone Joint Surg Am.* 2013;95-10:905-909.
52. Lustig S, Parratte S, Magnussen RA, et al. Lateral unicompartmental knee arthroplasty relieves pain and improves function in posttraumatic osteoarthritis. *Clin Orthop Relat Res.* 2012;470-1:69-76.
53. Gibson PH, Goodfellow JW. Stress radiography in degenerative arthritis of the knee. *J Bone Joint Surg Br.* 1986;68-4:608-609.
54. Yang NH, Nayeb-Hashemi H, Canavan PK, et al. Effect of frontal plane tibiofemoral angle on the stress and strain at the knee cartilage during the stance phase of gait. *J Orthop Res.* 2010;28-12:1539-1547.
55. Collier MB, Eickmann TH, Sukezaki F, et al. Patient, implant, and alignment factors associated with revision of medial compartment unicondylar arthroplasty. *J Arthroplasty.* 2006;21-6(suppl 2):108-115.
56. Citak M, Suero EM, Citak M, et al. Unicompartmental knee arthroplasty: is robotic technology more accurate than conventional technique? *Knee.* 2013;20-4:268-271.
57. Pandit H, Jenkins C, Beard DJ, et al. Mobile bearing dislocation in lateral unicompartmental knee replacement. *Knee.* 2010;17-6:392-397.