

The American Journal of Sports Medicine

<http://ajs.sagepub.com/>

Comparison of Lateral Closing-Wedge Versus Medial Opening-Wedge High Tibial Osteotomy on Knee Joint Alignment and Kinematics in the ACL-Deficient Knee

Anil S. Ranawat, Benedict U. Nwachukwu, Andrew D. Pearle, Hendrik A. Zuiderbaan, Kenneth D. Weeks and Saker Khamaisy

Am J Sports Med published online August 5, 2016

DOI: 10.1177/0363546516657824

The online version of this article can be found at:

<http://ajs.sagepub.com/content/early/2016/08/04/0363546516657824>

Published by:



<http://www.sagepublications.com>

On behalf of:

American Orthopaedic Society for Sports Medicine



Additional services and information for *The American Journal of Sports Medicine* can be found at:

Published online August 5, 2016 in advance of the print journal.

P<P

Email Alerts: <http://ajs.sagepub.com/cgi/alerts>

Subscriptions: <http://ajs.sagepub.com/subscriptions>

Reprints: <http://www.sagepub.com/journalsReprints.nav>

Permissions: <http://www.sagepub.com/journalsPermissions.nav>

>> [OnlineFirst Version of Record](#) - Aug 5, 2016

[What is This?](#)

Comparison of Lateral Closing-Wedge Versus Medial Opening-Wedge High Tibial Osteotomy on Knee Joint Alignment and Kinematics in the ACL-Deficient Knee

Anil S. Ranawat,^{*,†} MD, Benedict U. Nwachukwu,[†] MD, MBA, Andrew D. Pearle,[†] MD, Hendrik A. Zuiderbaan,[†] MD, Kenneth D. Weeks,[†] MD, and Saker Khamaisy,[†] MD
Investigation performed at the Hospital for Special Surgery, New York, New York, USA

Background: Lateral closing-wedge (LCW) and medial opening-wedge (MOW) high tibial osteotomies (HTOs) correct varus knee alignment and stabilize the anterior cruciate ligament (ACL)-deficient knee. Tibiofemoral and patellofemoral alignment and kinematics after HTO are not well quantified.

Purpose: To compare the effect of LCW and MOW HTO on tibiofemoral and patellofemoral alignment in the ACL-deficient knee.

Study Design: Controlled laboratory study.

Methods: Anterior drawer, Lachman, and pivot-shift tests were performed on cadaveric specimens (N = 16), and anterior tibial translation and tibial rotation were measured for the native and ACL-sectioned knee. The right and left knee of each cadaveric specimen underwent an LCW and MOW HTO, respectively, and stability testing was repeated. All cadavers underwent pre- and postosteotomy computerized tomography with 3-dimensional computer modeling to determine the effect of HTO on posterior tibial slope, as well as tibial and patellofemoral axial plane alignment (tibial axial rotation and patellar axial tilt).

Results: Correction to neutral coronal alignment was obtained with both osteotomy techniques; however, larger posterior tibial slope neutralization was achieved with LCW compared with MOW (mean \pm SD, $11^\circ \pm 3.8^\circ$ vs $5^\circ \pm 5^\circ$). LCW demonstrated a greater decrease in anterior tibial translation ($P < .05$) during Lachman testing, with translation values approximating those of the native knee, especially for the lateral compartment. A similar decrease in anterior tibial translation with LCW was not found during anterior drawer testing. Anterior tibial translation did not improve for either the Lachman or the anterior drawer test after MOW. Osteotomy type did not affect tibial rotation with pivot shift. Relative to MOW, LCW resulted in greater tibial axial rotation and patellar axial tilt ($7.7^\circ \pm 4^\circ$ and $5.6^\circ \pm 3.9^\circ$ [LCW], $2.8^\circ \pm 2.3^\circ$ and $2.4^\circ \pm 0.9^\circ$ [MOW], respectively; $P < .05$).

Conclusion/Clinical Relevance: LCW shows more reproducible posterior tibial slope neutralization and decreased anterior tibial translation in ACL deficiency compared with MOW; however, LCW is associated with increased external tibial axial rotation and lateral patellar tilt, which may adversely affect the patellofemoral joint. More work is needed to understand the clinical and functional outcome of these biomechanical findings in the ACL-deficient knee.

Keywords: ACL; high tibial osteotomy; outcomes; cadaver

Anterior cruciate ligament (ACL) injuries can lead to chronic tibiofemoral anterior laxity and rotatory instability.²⁵

*Address correspondence to Anil S. Ranawat, MD, Department of Orthopaedic Surgery, Hospital for Special Surgery, 535 East 70th Street, New York, NY 10021, USA (email: ranawataniil@hss.edu).

[†]Department of Orthopaedic Surgery, Hospital for Special Surgery, New York, New York, USA.

One or more of the authors has declared the following potential conflict of interest or source of funding: A.S.R.: paid consultant (Arthrex Inc, CONMED Linvatec, DePuy Mitek, and Stryker MAKO), IP royalties (ConforMIS). A.D.P.: paid consultant (Arthrex Inc, Stryker, and Zimmer), IP royalties (Zimmer).

The American Journal of Sports Medicine, Vol. XX, No. X
 DOI: 10.1177/0363546516657824
 © 2016 The Author(s)

Chronic ACL deficiency has been associated with progression to degenerative joint disease of the knee and progressive tibiofemoral varus alignment.^{7,32,34} In the ACL-deficient knee, isolated ACL reconstruction is an effective means for restoring stability to the knee; however, ACL reconstruction alone may not address all the pathomechanics, especially in the revision setting where there is more meniscal loss, subluxation, and tibiofemoral chondral damage.

High tibial osteotomy (HTO) has been recognized as an important treatment option for medial compartment arthritis in young, active patients and as a useful tool to stabilize the chronically ACL-deficient knee.^{8,16} Increasingly, HTO has been proposed as a singular or concomitant procedure with ACL reconstruction for restoring knee stability and addressing the coronal and sagittal plane in both

primary and revision settings.³⁰ Beyond improving coronal plane alignment, multiplanar HTO may normalize sagittal plane alignment in the ACL-deficient knee. More attention is now being paid to the role of knee sagittal plane alignment in ACL deficiency,¹¹ as the influence of posterior tibial slope is being increasingly investigated. In the cranial cruciate ligament-deficient (analogous to human ACL) canine knee, posterior tibial slope correction has long been recognized to improve stability.^{40,41} In humans, increased posterior tibial slope has been posited to influence sagittal plane shear forces and strains on the ACL, thereby affecting its loading behavior.^{17,21,33} Cadaveric studies have also demonstrated that iatrogenic changes in tibial inclination resulted in anterior shift of the tibia relative to the femur.⁴⁵ Clinical evidence confirms that increased posterior tibial slope is a risk factor for noncontact ACL injuries, as well as a cause for early failure of ACL reconstructions.^{11,15,44,46} Similarly, epidemiologic studies have highlighted a positive association between increased posterior tibial slope and the incidence of ACL injury.^{3,4,14}

Evidence comparing osteotomy options for the ACL-deficient knee is limited. Lateral closing-wedge (LCW) and medial opening-wedge (MOW) HTO can be performed in the ACL-deficient knee, but the ideal osteotomy has not yet been determined. Osteotomy type may influence coronal and sagittal plane tibiofemoral alignment, while also affecting tibial rotation and patellar mechanics. Prior evidence suggests that HTO may also influence patellar position and patellofemoral contact pressure.^{23,27,43} Unintended rotational and patellofemoral alignment changes²² may adversely influence outcome after HTO or complicate eventual conversion to knee arthroplasty.

The purpose of this study was to quantify the changes in tibiofemoral alignment, shape, and kinematics along with patellofemoral alignment in the ACL-deficient knee after LCW and MOW HTO. Specifically, anterior tibial translation, posterior tibial slope, rotational stability, tibial axial rotation, patellar axial tilt, and rotational stability were evaluated. We hypothesized that both LCW and MOW would have a positive effect on the kinematics of the ACL-deficient knee by decreasing the amount of anterior translation. Secondly, we hypothesized that these 2 techniques would not have a significantly different effect on tibial rotation and patellar axial tilt.

METHODS

Specimens

Eight fresh-frozen cadaveric hip-to-toe lower extremity specimens (16 paired knees) were used for this study (mean age \pm SD: 52 ± 10.3 years). Specimens were thawed for 48 hours at room temperature before testing and were placed supine on the operating table, allowing free and unrestricted range of motion at the hip and knee joints. Physical examination and a medial parapatellar arthrotomy of the knee were performed, and specimens were examined for alignment, deformities, ligamentous integrity, and

the absence of significant meniscal and articular cartilage lesions. All knees were deemed suitable for the study. All procedures were performed on both knees on the same day so as to standardize tissue quality.

Kinematics

A surgical navigation system with ACL-specific software (Surgetics; Praxim) as previously described^{5,10} was used for kinematic data acquisition. The navigation system has an accuracy of ± 1 mm per 1° .^{20,26,37} Reflective reference arrays were attached to the femur and the tibia, 15 cm above and below the joint line. These arrays were secured with two 4-mm Schanz pins. Instrumented stability testing included anterior translation with the knee at 30° and 90° of flexion, as well as pivot shift. Each test was performed at 3 time points: before sectioning of the ACL, after sectioning of the ACL, and after osteotomy. For the Lachman test, the femur was affixed to the operating table and the knee flexed to 30° . An anterior-directed force of a mean 10 kg (100 N) was applied to an eyelet screw on the tibial spine 10 cm from the joint line using a pulley and free weights. The anterior drawer test was performed in a similar manner with the femur affixed to the operating table and the knee bent to 90° , with the tibia perpendicular to the floor. Again, a pulley and free weights were used to create a force vector directly anterior to the tibial shaft. The pivot-shift testing was performed manually with the pelvis affixed to the operating table, the ankle internally rotated 20° , and a valgus force applied to the knee. Kinematic data were obtained as the knee was brought into flexion.

Tibiofemoral translation at 30° of knee flexion was defined as the translation from the tibiofemoral resting point at the beginning of each trial to the maximum anterior position of the tibia in the sagittal plane, in each of the lateral and medial compartments. Rotational motion during the pivot-shift test was measured as an increase in internal tibial rotation. Three trials of anterior drawer, Lachman, and mechanized pivot-shift tests were performed on each knee in the ACL-intact state. Three trials were performed to diminish the effect of any spurious readings. We then proceeded to transect the ACL, and 2 investigators visually and manually confirmed that complete sectioning of the ACL had occurred. Then, the anterior drawer, Lachman, and mechanized pivot-shift maneuvers were repeated.

Osteotomy

An MOW HTO was then performed on the left knee of each specimen and an LCW HTO on the contralateral right knee. As such, each knee served as its own control. Both operations were performed with the specimen in the supine position on a straight operating table.

Opening Wedge. The proximal tibia was exposed through a 10-cm anteromedial incision, and 2 reference Kirschner wires were drilled in the sagittal plane under fluoroscopic guidance: 1 above the osteotomy directly proximal to the insertion of the patellar ligament and a second

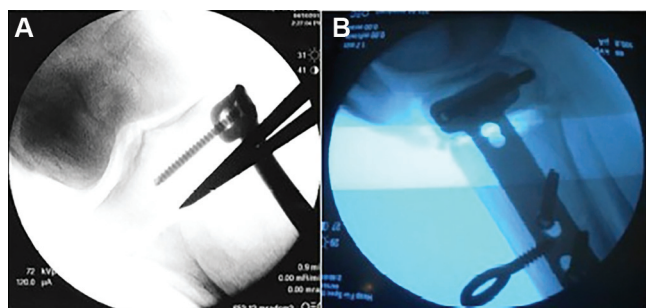


Figure 1. Intraoperative radiographs of a medial opening-wedge high tibial osteotomy. (A) Anteroposterior and (B) lateral radiographs demonstrate the osteotomy site and the Tomofix plate used to obtain fixation.

8 cm below the osteotomy. These Kirschner wires were parallel in the sagittal and axial planes. The sartorius fascia was incised proximal to the gracilis tendon. The incision went from the tibia to the ventral portion of the superficial medial collateral ligament (MCL). So, the gracilis and semitendinosus tendons were exposed and mobilized but not detached from bone. The anterior or ventral portion of the superficial MCL was aggressively elevated distally, leaving a portion of the dorsal superficial MCL and all of the deep MCL intact, as described by Lobenhoffer et al.³¹ The level of the osteotomy was exposed, starting 4 to 5 cm below the joint line. The osteotomy was obliquely aimed upward in the direction of the fibular head, about 2 cm below the lateral joint line, and was gradually opened to preserve a lateral bony bridge. A complete posterior osteotomy was performed, and the spreader for opening the osteotomy was placed as far posterior as possible (ie, as close to the posterior medial corner of the tibia as possible) so as to gain appropriate neutralization of the posterior tibial slope. The goal was for a maximal opening gap of posteromedial tibia, which was to be at least twice as great (8–10 mm) as the anterior tibial gap (4–5 mm). Finally, the open-wedge osteotomy was fixed with a self-locking plate (Tomofix; Synthes). The position of the Tomofix plate was exactly adjacent and thus slightly anterior to the posteriorly placed spreader (Figure 1).

Closing Wedge. To perform the LCW HTO, a 10-cm vertical incision was made along the lateral aspect of the tibia, and the tibialis anterior muscle of the proximal tibia was elevated to expose the proximal tibiofibular joint. A proximal osteotomy of the fibula was performed using an osteotome within the proximal third of the fibula through a separate incision. A retractor was placed under the lateral margin of the patellar tendon for protection, and another retractor was positioned along the posterolateral aspect of the tibia to protect the neurovascular structures. The osteotomy was commenced 2 cm below the lateral articular surface of the tibia. The proximal osteotomy was cut in parallel with the articular surface, and the distal osteotomy was started at least 8 to 10 mm inferior to the proximal osteotomy at the anterolateral part and 4 to 5 mm inferior in the posterolateral part (attempting to

achieve maximal slope correction) and cut obliquely to prevent injury to the patellar tendon. The lateral bone wedge was removed. To reduce the risk of intra-articular fractures, the lateral cortex and wedge were removed by using an osteotome and preserving 3 to 6 mm of the opposite cortical hinge. The medial tibial cortex was not completely osteotomized but perforated by multiple holes to work as a hinge when the osteotomy was closed. Finally, the closing-wedge osteotomy was fixed with a self-locking plate (Tomofix).

Imaging

Computed tomography (CT) scan (1-mm slices) was performed at the native knee for each specimen, as well as at the hip and ankle, to accurately quantify lower extremity alignment. The CT data were segmented manually and converted into 3-dimensional (3D) computer models using Mimics 10.11 software (Materialize). The preosteotomy CT scan was segmented into 3 parts: femur, tibia, and patella. The postosteotomy CT was segmented into 4 parts: femur, tibia proximal to osteotomy, tibia distal to osteotomy, and patella. By segmentation, the surface of each bone was digitized into a constellation of points (clouds), and the geometrical relationship between each bone was assessed with reference to the original CT. Rotation was calculated from a rotation matrix using an *X*, *Y*, *Z* rotation sequence. The tibial tuberosity was used as a primary reference point for rotation.

Mathematical Modeling (Iterative Closest Point Method)

A software code (Matlab 2012; MathWorks Inc) based on an iterative closest point algorithm was developed to measure tibial rotation and changes in patellar axial tilt after HTO. The iterative closest point algorithm is a commonly used method for matching 3D surfaces.² The algorithm seeks to minimize the sum of squared distances between 2 clouds of points and finds the rigid transformation (translation and rotation) that best aligns these 2 clouds. Each cloud of points can represent a digitized surface. Previous studies have shown a high degree of accuracy using the iterative closest point algorithm for matching bone surfaces^{1,29} and orthopaedic implants.^{9,38}

As part of the current study, rotation measurement was performed in several steps using the 3D models obtained from the segmented CT scans. First, to bring the pre- and postoperative CTs to the same reference point, the code calculated 3D rotation and translation needed for the part of the postoperative tibia (Figure 2B) proximal to the osteotomy to overlap and match identically with the preoperative tibia (Figure 2A). Based on this calculated rotation and translation, the proximal and distal segments of the postoperative tibia were moved as one unit to this new position on the coordinate grid where the proximal parts of the pre- and postoperative tibia were superimposed (Figure 2C). In the next step, the code calculated the 3D rotation and translation needed for the part of the tibia distal to the osteotomy to move from its new position

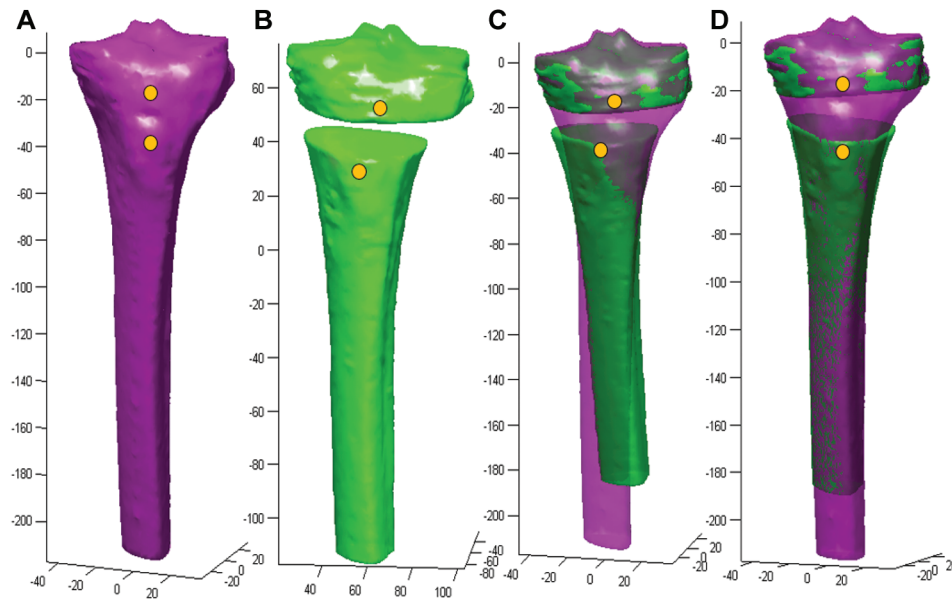


Figure 2. Iterative closest point analysis to assess tibial rotation. Three-dimensional model demonstrating computation measurements for tibial rotation and alignment associated with HTO. (A) Preosteotomy tibia, (B) isolated postosteotomy tibial components with proximal tibia and tibial diaphyseal segments, (C) pre- and postosteotomy tibial segments superimposed, (D) pre- and postosteotomy tibial segments after computer-calculated rotation and translation to ensure accurate superimposition. HTO, high tibial osteotomy.

on the coordinate grid to a new position that overlaps the preoperative tibia (Figure 2D); therefore, the code calculated reverse tibial 3D rotation and translation. Tibial axial rotation was measured relative to the tibial mechanical axis, and slope correction was measured relative to the posterior condylar axis of the tibia. Using the same code and the same steps, the change in axial patellar tilt was measured relative to the femur (Figure 3); the postoperative femur superimposed the preoperative femur in the first step, and in the second step, the postoperative patella superimposed the preoperative patella as the change in axial patellar tilt after HTO was measured. Of note, to calculate posterior tibial slope alignment using our iterative closest point method, statistical shape modeling was used, with tibial slope representing a shape parameter. Patellofemoral and tibial alignments were derived, however, from alignment parameters.

Statistical Analysis

Student *t* tests were used to compare the difference between the osteotomized specimen and the native specimen with regard to LCW and MOW. Comparison between LCW and MOW was performed with attention to the following dependent variables: coronal alignment, posterior tibial slope, tibial axial rotation, and patellar axial tilt. Student *t* tests were also used to detect a difference in tibial translation and rotation among specimens based on ACL (deficient vs native) and osteotomy (osteotomy vs native) status. Pearson product moment correlation was used to determine the correlation of the change in patellar

tilt to the tibial rotation after HTO. $P < .05$ was considered statistically significant. Statistical analyses were performed using STATA software (version 12.1; Statacorp).

RESULTS

Tibiofemoral

The mean (\pm SD) coronal alignment after MOW and LCW was $2.1^\circ \pm 1.3^\circ$ and $0.8^\circ \pm 1.7^\circ$ of valgus, respectively; similarly, the mean posterior tibial slope was $1.0^\circ \pm 0.5^\circ$ and $-0.9^\circ \pm 1.2^\circ$, respectively. The mean tibial coronal alignment correction after MOW was not significantly different compared with alignment correction after LCW (Table 1). The mean posterior tibial slope neutralization was $7.1^\circ \pm 1.8^\circ$ after LCW and $5.1^\circ \pm 0.9^\circ$ after MOW. The change from pre- to postoperative in the tibial slope was significantly different between the procedures ($P = .025$).

Kinematic Testing

Sectioning the ACL resulted in a statistically significant increase in anterior tibial translation during anterior drawer and Lachman testing. For pivot-shift testing, ACL sectioning resulted in nonsignificantly increased tibial internal rotation. In the ACL-deficient knee, the tibia translated, on average, an additional 2.1 ± 1.2 mm during anterior drawer and 4.1 ± 2.1 mm during Lachman testing. During pivot-shift testing, ACL-deficient knees had, on average, an additional 1.57° of internal rotation.

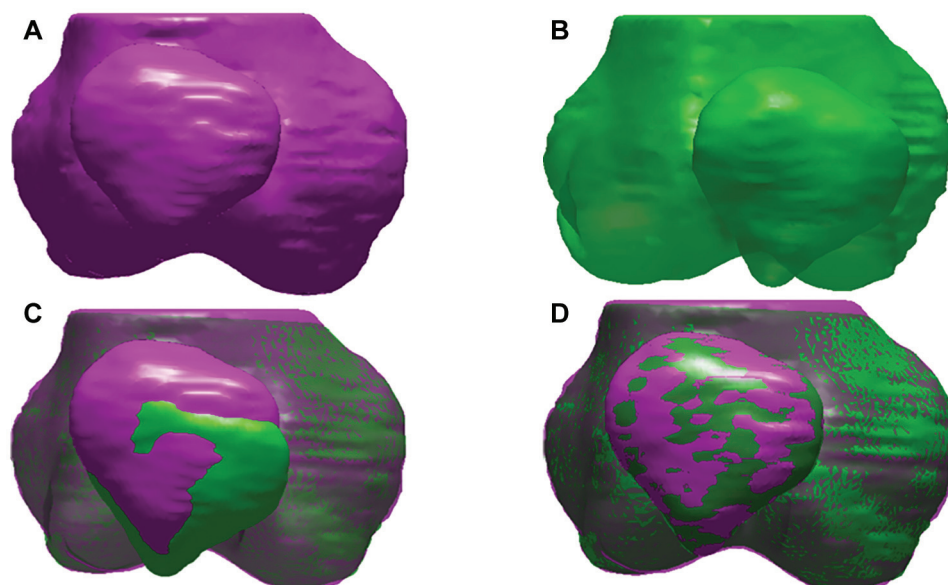


Figure 3. Iterative closest point analysis to assess patellofemoral tilt. Three-dimensional model demonstrating computational measurements for patellofemoral rotation and alignment associated with HTO. (A) Preosteotomy patellar position and alignment, (B) postosteotomy patellar position and alignment, (C) pre- and postosteotomy patellae superimposed, (D) pre- and postosteotomy patellae after computer-calculated rotation and translation required to ensure accurate superimposition. HTO, high tibial osteotomy.

TABLE 1
Coronal and Sagittal Alignment^a

	Right (LCW)	Left (MOW)	P Value
Coronal alignment, deg			
Native	5.1 ± 1.6	5.1 ± 1.6	
	varus	varus	
Postoperative	0.8 ± 1.7	2.1 ± 1.3	
	valgus	valgus	
Change	5.9 ± 1.8	7.2 ± 0.95	.08
Posterior tibial slope, deg			
Native	6.2 ± 0.9	6.2 ± 0.9	
Postoperative	-0.9 ± 1.2	1.0 ± 0.5	
Change	7.1 ± 1.8	5.1 ± 0.9	.025

^aData are reported as mean ± SD. LCW, lateral closing wedge; MOW, medial opening wedge.

When LCW osteotomy was performed in the ACL-deficient knee, there was a statistically significant decrease in postosteotomy lateral compartment anterior tibial translation during Lachman testing ($P = .003$) and a decrease in medial compartment anterior tibial translation that was not statistically significant ($P = .09$) (Table 2). When a MOW was performed, however, there were no differences in anterior tibial translation for the medial or lateral compartment. For the anterior drawer test, no significant differences were found with either osteotomy type for anterior tibial translation (Table 3). Similarly, for the pivot shift, no significant differences were found for internal tibial rotation. For LCW, the difference between the ACL-deficient knee and native was 1.51° and the difference between the osteotomy

TABLE 2
Change in Anterior Tibial Translation During Lachman Testing Based on Osteotomy Type and ACL Status^a

	Anterior Tibial Translation, mm		P Value
	Deficient vs Native	Osteotomy vs Native	
LCW			
Medial	4.75	3.05	.090
Lateral	5.25	1.75	.003
MOW			
Medial	2.7	2.425	.790
Lateral	3.375	2.75	.410

^aACL, anterior cruciate ligament; LCW, lateral closing wedge; MOW, medial opening wedge.

knee and native was 1.91° ($P = .751$). For MOW, the difference between the ACL-deficient knee and native was 1.65° and the difference between the osteotomy knee and native was -1.19° ($P = .228$).

Patellofemoral

After LCW, in all cadavers, the distal tibia was significantly more externally rotated and the patella significantly laterally tilted (Table 4). However, after MOW, in 4 specimens the tibia distal to the osteotomy was rotated externally and the patella tilted laterally, and in 4 specimens the tibia was rotated internally and the patella tilted medially. The mean absolute tibial rotation and mean absolute change in patellar axial tilt were significantly higher in the

TABLE 3
Change in Anterior Tibial Translation
During Anterior Drawer Testing Based
on Osteotomy Type and ACL Status^a

	Anterior Tibial Translation, mm		P Value
	Deficient vs Native	Osteotomy vs Native	
LCW			
Medial	1.8	2.3	.54
Lateral	1.175	1.05	.87
MOW			
Medial	2.725	2.325	.43
Lateral	2.5	2.65	.74

^aACL, anterior cruciate ligament; LCW, lateral closing wedge; MOW, medial opening wedge.

LCW group than in the MOW group ($P = .009$ and $.04$, respectively). Within the MOW group, tibias that rotated externally had a mean external tibial rotation of $4.2^\circ \pm 2.4^\circ$ and mean lateral patellar tilt of $2.5^\circ \pm 0.8^\circ$, with no significant difference compared with those tibias that rotated internally, with mean internal tibial rotation of $1.4^\circ \pm 0.8^\circ$ ($P = .065$) and medial patellar tilt of $2.4^\circ \pm 1.2^\circ$. The change in patellar axial tilt was correlated only with tibial rotation, with a moderately positive Pearson correlation product ($r^2 = 0.65$). However, there were no correlations between patellar axial tilt and slope correction or between patellar axial tilt and coronal alignment correction.

DISCUSSION

To our knowledge, this is the first biomechanical study comparing LCW and MOW tibial and patellofemoral alignment kinematics. We found that LCW HTO demonstrates more reliable slope correction than does MOW HTO; however, LCW is inferior to MOW in maintaining neutral patellofemoral mechanics. As such, we only partially accept our hypothesis due to the differential efficacy of LCW versus MOW HTO on both tibiofemoral and patellofemoral mechanics. Patients with multiple failed ACL reconstructions, or patients with clear anatomic risk factors for ACL injury, may benefit more from a leveling LCW HTO as it confers a more protective environment to normalized ACL kinematics; however, this benefit may be obtained at the expense of the patellofemoral joint.

In this study, we found that LCW HTO provided more significant slope neutralization than did MOW HTO while concurrently decreasing the magnitude of anterior tibial translation in the ACL-deficient knee. The relationship between sagittal plane mechanics and changes in posterior tibial slope is well documented.^{4,17,39} A linear association between increased anterior tibial translation, tibial shear force, and ACL strain has been shown with increasing posterior tibial slope; however, few studies have investigated the effects of slope neutralization in the ACL-deficient knee. Shelburne et al³⁹ used a 3D musculoskeletal computer model to show that anterior tibial translation could

TABLE 4
Changes in Axial Alignment^a

	LCW	MOW	P Value
External tibial rotation, deg	7.7 ± 4	2.8 ± 2.3	.009
Lateral patellar tilt, deg	5.6 ± 3.9	2.4 ± 0.9	.04

^aData are reported as mean \pm SD. LCW, lateral closing wedge; MOW, medial opening wedge.

be decreased in standing, walking, and squatting by lessening the posterior tibial slope. Their results were consistent with the in vivo radiographic results of Dejour and Bonnin,¹² which demonstrated a change of 6 mm in anterior tibial translation with 10° change in slope. The findings of this study were in agreement but less robust, as we found a decrease of 2.6 mm in anterior tibial translation with a 7° change in posterior tibial slope when using an LCW. The discrepancy between our study and previously reported values for anterior tibial translation may be explained by our lack of physiologic axial load as applied in prior studies.¹² In one of the few studies examining alterations in anterior tibial translation in association with posterior tibial slope neutralization in ACL-deficient knees, Voos et al⁴⁵ also noted a decrease in translation during clinical testing (pivot shift) but no significant improvements in anterior tibial translation during Lachman testing. The osteotomy in that study differed from ours as it was a pure sagittal osteotomy aimed for only 5° of slope correction from the native state, which may account for the differences in kinematic testing and is unrealistic clinically in the ACL-deficient knee. More recently, Dejour et al¹¹ demonstrated good medium-term outcome in patients undergoing revision ACL reconstruction who had their posterior tibial slope addressed at the time of second revision. Our findings, in conjunction with these prior studies, highlight the importance of posterior tibial slope neutralization and its effect on knee stability. Furthermore, our findings suggest that posterior tibial slope is a modifiable factor for complex and primary revision ACL surgery.

We chose to use 2 commonly used HTOs rather than a pure sagittal correction in this study so as to evaluate clinically relevant outcomes, as well as investigate the differences between these 2 types of surgeries. Randomized controlled studies on LCW HTO versus MOW HTO have suggested that LCW may produce more accurate correction⁶ despite an equivalence in medium- to long-term outcome.¹³ A meta-analysis by Smith et al⁴² investigated outcomes of studies following LCW and MOW osteotomies and demonstrated no difference in complication rates or outcome scores. Radiographically, they found opening-wedge procedures resulted in lower patellar height and an increase in posterior tibial slope, both of which were significant in comparison with closing-wedge techniques. Our finding that LCW has significantly better posterior tibial slope neutralization echoes these prior results. In addition, we found, as in prior studies, no difference in coronal alignment between the 2 osteotomy techniques.

Another novel aspect of this study is looking at 2 different osteotomy techniques and their effect on patellofemoral kinematics. We demonstrated increased distal tibial external rotation and lateral patellar tilt after LCW compared with MOW HTO. One prior study looking only at MOW found (similar to the present study) that MOW did not significantly alter patellofemoral mechanics.⁴⁷ The significant difference between absolute rotation after LCW and MOW appears to be related to the fibular osteotomy and the lateral tibial cortical hinge preserved in MOW HTO, therefore restricting excessive tibial rotation. Patellar tilt consequently tends to follow the distal tibia as the osteotomies are performed above the tibial tubercle. The clinical significance relating to our finding for increased tibial rotation and patellar axial tilt is worthy of further investigation. Patellofemoral alignment and kinematics have been shown to predict risk for progression to patellofemoral arthritis.³⁶ The effect of alterations in native patellofemoral mechanics after HTO, however, is variably interpreted in the literature with no clear consensus on the clinical outcome of this finding.²⁸ Our current lack of understanding may be a result of inattention to the differences between LCW and MOW HTO. With regard to total knee arthroplasty (TKA), however, it has been established that alterations in patella mechanics associated with HTO may result in more technically challenging TKA surgery, as well as altered post-TKA kinematics.^{18,19,24}

This study has certain limitations. First, this investigation was a laboratory study using fresh-frozen cadavers. Although such studies provide valuable information for biomechanical testing, our in vivo assessment is limited, and we cannot account for the soft tissue and muscular interplay responsible for dynamic stability in the knee joint. Specifically, HTO is most commonly performed in the setting of chronic ACL insufficiency and corresponding laxity of knee soft tissue structures. In our study, the ACL was sectioned acutely, and this may not be representative of in vivo knee injury kinematics. The laboratory nature of our investigation, however, paves the way for further clinical assessments and research to better evaluate knee instability in ACL-deficient patients undergoing HTO. Another limitation of the current study is the testing apparatus. Our laboratory design attempted to replicate the 3 commonly used physical examination maneuvers—faithful replication of these tests requires an absence of axial loading. However, this design choice limits the generalizability of our findings as we do not submit our cadaveric specimens to physiologic conditions and, as such, can make no inferences as to how physiologic axial loading would alter our findings. On the basis of the work of McLean et al,³³ we suspect that adding axial load would likely mimic or accentuate improvements in anterior tibial translation found in this study. Our shift data were limited because of the ineffectiveness of our machine at reproducing our results. In addition, our postosteotomy kinematic testing was inherently limited. We found that anterior tibial translation was significantly altered only for the Lachman but not for anterior drawer testing. Plastic deformation of translation testing devices over several runs could potentially contribute to decreased accuracy of anterior tibial

translation measurement; however, no significant deformation was noted over the course of our own laboratory investigations. Nonsignificant findings may have been a result of supplementary restraining effects of the knee soft tissue envelope augmenting HTO in vivo, which is not faithfully reproduced in a cadaveric specimen. Specifically, we believe the overresection of the MCL during MOW and laxity of the lateral side with LCW may cause excessive anterior tibial translation in higher flexion at time zero due to an absence of medial-side healing and the lateral-side scarring that occur in vivo. Finally, technical considerations should be noted. Specifically, we believe that, with the technique described in this study, plate position likely has a negligible effect on the degree of posterior tibial slope neutralization with MOW; however, this has not been formally studied. As assessed by Noyes et al³⁵ in comparison to LCW, MOW can be more technically challenging with regard to controlling for multiplanar alignment. Noyes et al described a 3-triangle concept with regard to MOW: coronal (valgus) angle, the oblique opening-wedge angle along the anteromedial tibial cortex, and the gap angle. Attention is paid to these 3 triangles during MOW to appropriately correct axial alignment while maintaining or modifying tibial slope. The technical challenge of MOW was attenuated in our study because all procedures were performed by a single fellowship-trained surgeon performing a high volume of MOW in routine practice.

CONCLUSION

LCW HTO demonstrates more reliable slope correction than does MOW HTO. However, LCW is inferior to MOW in maintaining neutral patellofemoral mechanics. More work is needed to continue investigating the effect of MOW and LCW HTO on knee kinematics in the ACL-deficient knee.

REFERENCES

1. Beek M, Small CF, Ellis RE, Sellens RW, Pichora DR. Bone alignment using the iterative closest point algorithm. *J Appl Biomech*. 2010; 26(4):526-530.
2. Besl PJ, McKay ND. A method for registration of 3-D shapes. *IEEE Trans Pattern Anal Mach Intell*. 1992;14(2):239-256.
3. Boden BP, Breit I, Sheehan FT. Tibiofemoral alignment: contributing factors to noncontact anterior cruciate ligament injury. *J Bone Joint Surg Am*. 2009;91(10):2381-2389.
4. Brandon ML, Haynes PT, Bonamo JR, Flynn MI, Barrett GR, Sherman MF. The association between posterior-inferior tibial slope and anterior cruciate ligament insufficiency. *Arthroscopy*. 2006;22(8):894-899.
5. Brophy RH, Voos JE, Shannon FJ, et al. Changes in the length of virtual anterior cruciate ligament fibers during stability testing: a comparison of conventional single-bundle reconstruction and native anterior cruciate ligament. *Am J Sports Med*. 2008;36(11):2196-2203.
6. Brouwer RW, Bierma-Zeinstra SM, van Raaij TM, Verhaar JA. Osteotomy for medial compartment arthritis of the knee using a closing wedge or an opening wedge controlled by a Puddu plate: a one-year randomised, controlled study. *J Bone Joint Surg Br*. 2006;88(11):1454-1459.
7. Burks RT, Metcalf MH, Metcalf RW. Fifteen-year follow-up of arthroscopic partial meniscectomy. *Arthroscopy*. 1997;13(6):673-679.
8. Cantin O, Magnussen RA, Corbi F, Servien E, Neyret P, Lustig S. The role of high tibial osteotomy in the treatment of knee laxity:

- a comprehensive review. *Knee Surg Sports Traumatol Arthrosc.* 2015;23(10):3026-3037.
9. Citak M, Suero EM, Citak M, et al. Unicompartmental knee arthroplasty: is robotic technology more accurate than conventional technique? *Knee.* 2013;20(4):268-271.
 10. Colombet P, Robinson J, Christel P, Franceschi JP, Djian P. Using navigation to measure rotation kinematics during ACL reconstruction. *Clin Orthop Relat Res.* 2007;454:59-65.
 11. Dejour D, Saffarini M, Demey G, Baverel L. Tibial slope correction combined with second revision ACL produces good knee stability and prevents graft rupture. *Knee Surg Sports Traumatol Arthrosc.* 2015;23(10):2846-2852.
 12. Dejour H, Bonnin M. Tibial translation after anterior cruciate ligament rupture: two radiological tests compared. *J Bone Joint Surg Br.* 1994;76(5):745-749.
 13. Duivenvoorden T, Brouwer RW, Baan A, et al. Comparison of closing-wedge and opening-wedge high tibial osteotomy for medial compartment osteoarthritis of the knee: a randomized controlled trial with a six-year follow-up. *J Bone Joint Surg Am.* 2014;96(17):1425-1432.
 14. El-Azab H, Glabgyl P, Paul J, Imhoff AB, Hinterwimmer S. Patellar height and posterior tibial slope after open- and closed-wedge high tibial osteotomy: a radiological study on 100 patients. *Am J Sports Med.* 2010;38(2):323-329.
 15. Feucht MJ, Mauro CS, Brucker PU, Imhoff AB, Hinterwimmer S. The role of the tibial slope in sustaining and treating anterior cruciate ligament injuries. *Knee Surg Sports Traumatol Arthrosc.* 2013;21(1):134-145.
 16. Giffin JR, Shannon FJ. The role of the high tibial osteotomy in the unstable knee. *Sports Med Arthrosc.* 2007;15(1):23-31.
 17. Giffin JR, Vogrin TM, Zantop T, Woo SL, Harner CD. Effects of increasing tibial slope on the biomechanics of the knee. *Am J Sports Med.* 2004;32(2):376-382.
 18. Haddad FS, Bentley G. Total knee arthroplasty after high tibial osteotomy: a medium-term review. *J Arthroplasty.* 2000;15(5):597-603.
 19. Haslam P, Armstrong M, Geutjens G, Wilton TJ. Total knee arthroplasty after failed high tibial osteotomy long-term follow-up of matched groups. *J Arthroplasty.* 2007;22(2):245-250.
 20. Hufner T, Geerling J, Kfuri M Jr, et al. Computer assisted pelvic surgery: registration based on a modified external fixator. *Comput Aided Surg.* 2003;8(4):192-197.
 21. Imran A, O'Connor JJ. Theoretical estimates of cruciate ligament forces: effects of tibial surface geometry and ligament orientations. *Proc Inst Mech Eng H.* 1997;211(6):425-439.
 22. Jang KM, Lee JH, Park HJ, Kim JL, Han SB. Unintended rotational changes of the distal tibia after biplane medial open-wedge high tibial osteotomy. *J Arthroplasty.* 2016;31(1):59-63.
 23. Javidan P, Adamson GJ, Miller JR, et al. The effect of medial opening wedge proximal tibial osteotomy on patellofemoral contact. *Am J Sports Med.* 2013;41(1):80-86.
 24. Kazakos KJ, Chatzipapas C, Verettas D, Galanis V, Xarchas KC, Psilakis I. Mid-term results of total knee arthroplasty after high tibial osteotomy. *Arch Orthop Trauma Surg.* 2008;128(2):167-173.
 25. Kennedy JC, Weinberg HW, Wilson AS. The anatomy and function of the anterior cruciate ligament: as determined by clinical and morphological studies. *J Bone Joint Surg Am.* 1974;56(2):223-235.
 26. Khadem R, Yeh CC, Sadeghi-Tehrani M, et al. Comparative tracking error analysis of five different optical tracking systems. *Comput Aided Surg.* 2000;5(2):98-107.
 27. Laprade RF, Engebretsen L, Johansen S, Wentorf FA, Kurtenbach C. The effect of a proximal tibial medial opening wedge osteotomy on posterolateral knee instability: a biomechanical study. *Am J Sports Med.* 2008;36(5):956-960.
 28. Lee YS, Lee SB, Oh WS, Kwon YE, Lee BK. Changes in patellofemoral alignment do not cause clinical impact after open-wedge high tibial osteotomy. *Knee Surg Sports Traumatol Arthrosc.* 2016;24(1):129-133.
 29. Lee YS, Seon JK, Shin VI, Kim GH, Jeon M. Anatomical evaluation of CT-MRI combined femoral model. *Biomed Eng Online.* 2008;7:6.
 30. Li Y, Zhang H, Zhang J, Li X, Song G, Feng H. Clinical outcome of simultaneous high tibial osteotomy and anterior cruciate ligament reconstruction for medial compartment osteoarthritis in young patients with anterior cruciate ligament-deficient knees: a systematic review. *Arthroscopy.* 2015;31(3):507-519.
 31. Lobenhoffer P, Agneskirchner J, Zoch W. Open valgus alignment osteotomy of the proximal tibia with fixation by medial plate fixator [in German]. *Orthopade.* 2004;33(2):153-160.
 32. Louboutin H, Debarge R, Richou J, et al. Osteoarthritis in patients with anterior cruciate ligament rupture: a review of risk factors. *Knee.* 2009;16(4):239-244.
 33. McLean SG, Oh YK, Palmer ML, et al. The relationship between anterior tibial acceleration, tibial slope, and ACL strain during a simulated jump landing task. *J Bone Joint Surg Am.* 2011;93(14):1310-1317.
 34. Neyret P, Donell ST, Dejour H. Results of partial meniscectomy related to the state of the anterior cruciate ligament: review at 20 to 35 years. *J Bone Joint Surg Br.* 1993;75(1):36-40.
 35. Noyes FR, Goebel SX, West J. Opening wedge tibial osteotomy: the 3-triangle method to correct axial alignment and tibial slope. *Am J Sports Med.* 2005;33(3):378-387.
 36. Otsuki S, Nakajima M, Okamoto Y, et al. Correlation between varus knee malalignment and patellofemoral osteoarthritis. *Knee Surg Sports Traumatol Arthrosc.* 2016;24(1):176-181.
 37. Pearle AD, Solomon DJ, Wanich T, et al. Reliability of navigated knee stability examination: a cadaveric evaluation. *Am J Sports Med.* 2007;35(8):1315-1320.
 38. Popescu F, Viceconti M, Grazi E, Cappello A. A new method to compare planned and achieved position of an orthopaedic implant. *Comput Methods Programs Biomed.* 2003;71(2):117-127.
 39. Shelburne KB, Kim HJ, Sterett WI, Pandy MG. Effect of posterior tibial slope on knee biomechanics during functional activity. *J Orthop Res.* 2011;29(2):223-231.
 40. Slocum B, Devine T. Cranial tibial wedge osteotomy: a technique for eliminating cranial tibial thrust in cranial cruciate ligament repair. *J Am Vet Med Assoc.* 1984;184(5):564-569.
 41. Slocum B, Slocum TD. Tibial plateau leveling osteotomy for repair of cranial cruciate ligament rupture in the canine. *Vet Clin North Am Small Anim Pract.* 1993;23(4):777-795.
 42. Smith TO, Sexton D, Mitchell P, Hing CB. Opening- or closing-wedged high tibial osteotomy: a meta-analysis of clinical and radiological outcomes. *Knee.* 2011;18(6):361-368.
 43. Stoffel K, Willers C, Korshid O, Kuster M. Patellofemoral contact pressure following high tibial osteotomy: a cadaveric study. *Knee Surg Sports Traumatol Arthrosc.* 2007;15(9):1094-1100.
 44. Todd MS, Lalliss S, Garcia E, DeBerardino TM, Cameron KL. The relationship between posterior tibial slope and anterior cruciate ligament injuries. *Am J Sports Med.* 2010;38(1):63-67.
 45. Voos JE, Suero EM, Citak M, et al. Effect of tibial slope on the stability of the anterior cruciate ligament-deficient knee. *Knee Surg Sports Traumatol Arthrosc.* 2012;20(8):1626-1631.
 46. Wordeman SC, Quatman CE, Kaeding CC, Hewett TE. In vivo evidence for tibial plateau slope as a risk factor for anterior cruciate ligament injury: a systematic review and meta-analysis. *Am J Sports Med.* 2012;40(7):1673-1681.
 47. Yang JH, Lee SH, Nathawat KS, Jeon SH, Oh KJ. The effect of biplane medial opening wedge high tibial osteotomy on patellofemoral joint indices. *Knee.* 2013;20(2):128-132.